

University of Padova
Department of Ophthalmology

Peripapillary Microperimetry and Glaucoma

Edoardo Midena, MD
Professor of Ophthalmology and Visual Sciences

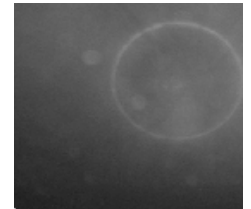
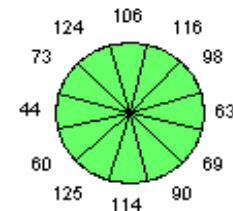
INTRODUCTION

Glaucoma is an optic neuropathy characterized by a specific and progressive injury to retinal nerve fiber layer (RNFL). Early detection and prevention of RNFL glaucomatous damage is mandatory because RNFL injury is largely irreversible. RNFL damage has been shown to precede visual field loss, therefore RNFL morphologic and functional evaluation is essential in detecting and monitoring glaucoma.

The aim of this study was: to evaluate the role of peripapillary microperimetry in detecting RNFL functional damage in glaucomatous eyes.

M & M

- ❖ **88 EYES (46 SUBJECTS):**
 - **35** glaucomatous eyes.
 - **31** ocular hypertension eyes (OH)*.
 - **24** matched control eyes.
- ❖ **MEAN AGE:** 59.3 ± 14.7 years (range 18-87 yrs)
- ❖ **VISUAL ACUITY (ETDRS charts):** from 20/40 to 20/20.
- ❖ **VISUAL FIELD TESTING** performed by Swedish Interactive Thresholding Algorithm (**SITA**) **Standard 24-2** perimetry (Carl Zeiss Meditec Inc., USA) in patients with ocular hypertension and glaucoma.
- ❖ **OPTICAL COHERENCE TOMOGRAPHY** performed by **Fast RNFL Thickness (3.4)** in 12 sectors, in patients with ocular hypertension, glaucoma and in matched control.

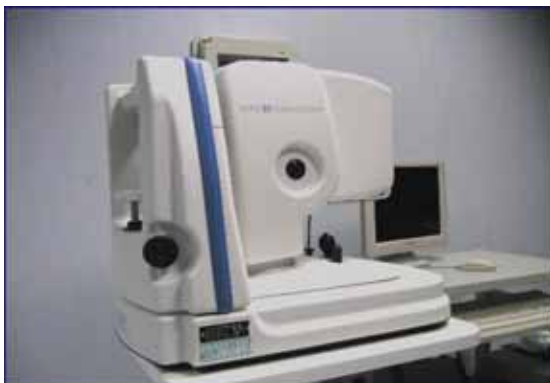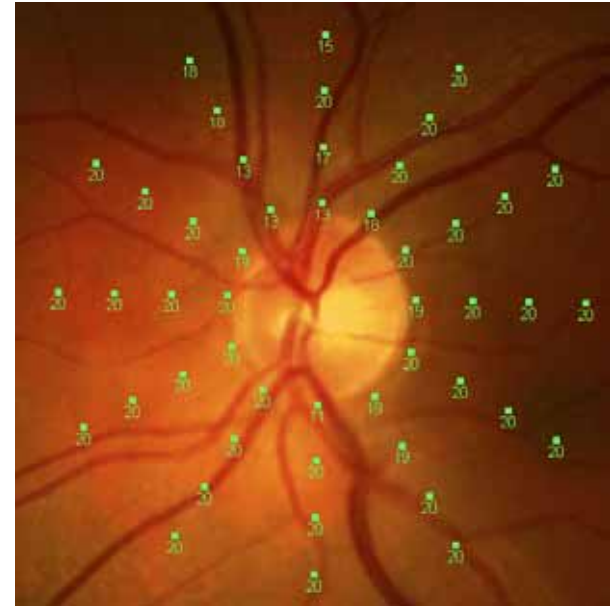


M & M

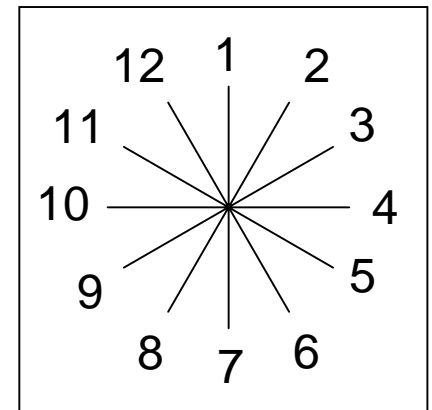
❖ MICROPERIMETRY (MP1):

Peripapillary grid:

- Fixation target: cross 1 °
- Stimuli size: Goldmann III
- Threshold pattern: 4-2-1
- Starting stimulus attenuation: 16 dB
- Stimuli number in each radial direction: 4
- First stimulus distance from optic disk head: 1 °
- Distance between stimuli: 2 °



MP1 Microperimeter - Nidek Technologies



RESULTS

- ❖ At OCT analysis: significant differences in all retinal sectors ($P < 0.0001$) between normal and OH vs glaucoma group were found, whereas between normal vs OH group the differences were statistically significant just in sectors 3, 4, 5, 6 and 7 ($P < 0.0001$).
- ❖ Peripapillary microperimetric data analysis showed:

	Normal	OH	Glaucoma
dB	19.2 ± 1.8	17.5 ± 4.2	10.1 ± 6.9

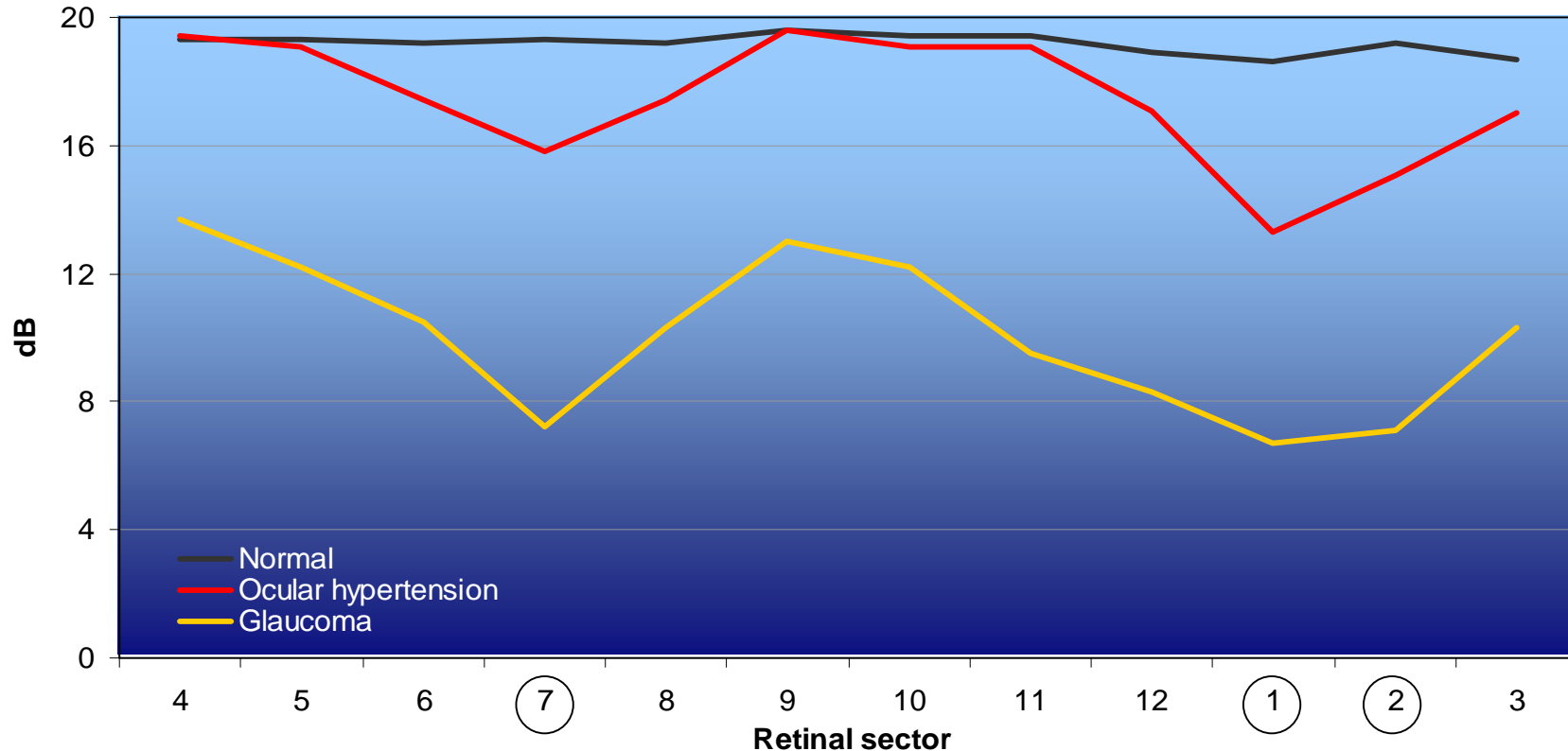
- ❖ Progressive, significant reduction of peripapillary sensitivity was documented in all retinal sectors in glaucomatous eyes ($P < 0.0001$) and in sectors 1-2 and 7 in OH eyes ($P < 0.0001$) vs control eyes.

M & M

- ❖ The differences of sensitivity (dB) and thickness (micron) mean measurement among the 3 diagnostic groups (glaucoma, OH and normal subject) were evaluated by 2-way analysis of variance (group x retinal sector) with repeated measures on one factor (retinal sector).
- ❖ Scheffe's test was used for post-hoc multiple comparisons.
- ❖ Receiver operating characteristic curves (ROC) were traced for both instruments (microperimetry and OCT) to assess their ability to differentiate ocular hypertension or glaucoma eyes from normal eyes. The best combination of sensitivity and specificity in each retinal sector was detected and data from both instrument were plotted in the same chart.
- ❖ In all statistical analyses, $p < 0.05$ was considered statistically significant. Statistical analyses were performed by SAS[®] v.8.2 Statistical package on personal computer.

Microperimetric measurements Peripapillary sensitivity profile by retinal sector and group of patients

(mean values)



Comparison among sensitivity profiles: ANOVA with repeated measures, $F_{[22,814]}=3.06$, $p<0.0001$

In all retinal sectors Glaucoma group provide lower sensitivity mean values than the other two groups

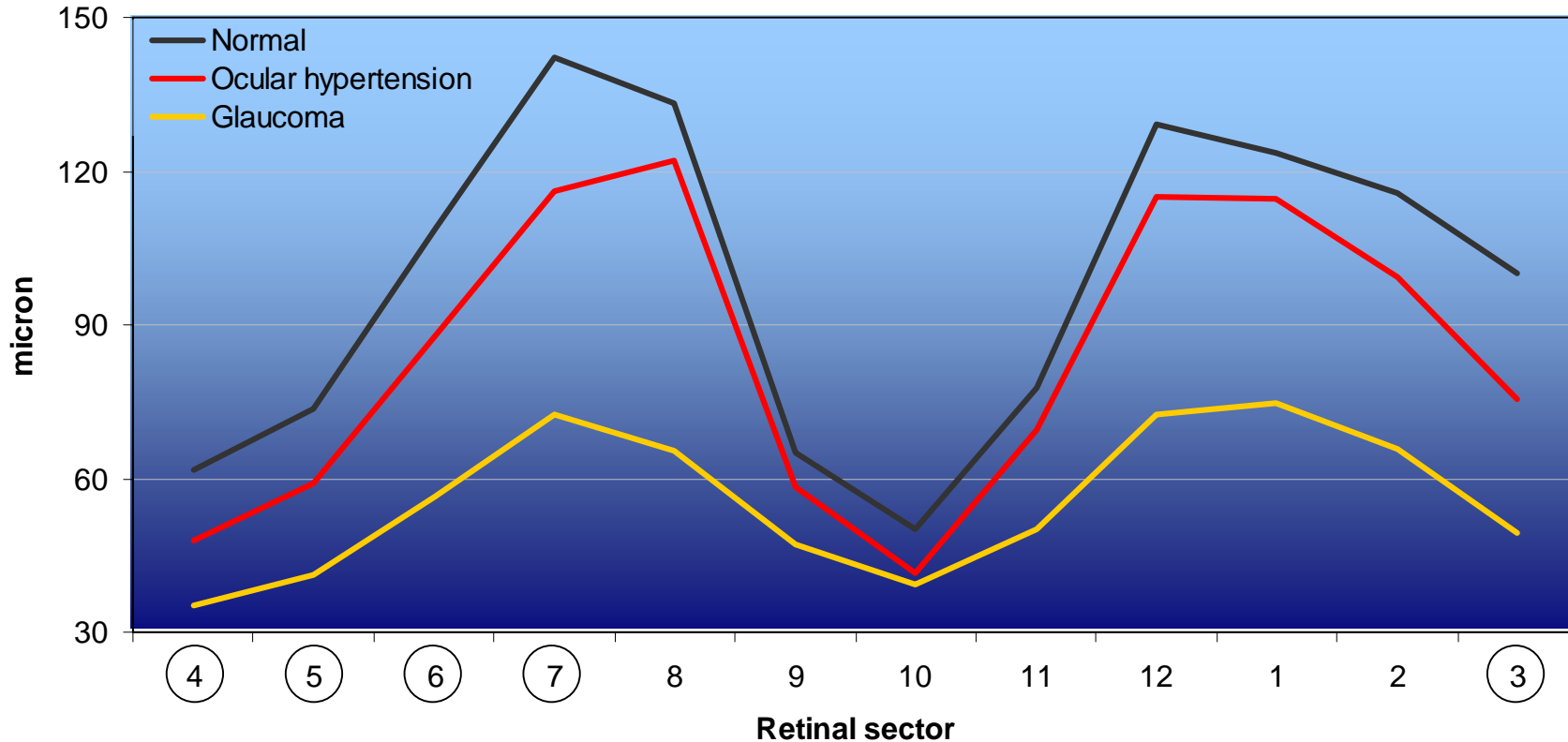
○ Sectors in which OH group mean values are significantly ($p<0.05$) lower than normal ones

OCT measurements

Peripapillary thickness profile

by retinal sector and group of patients

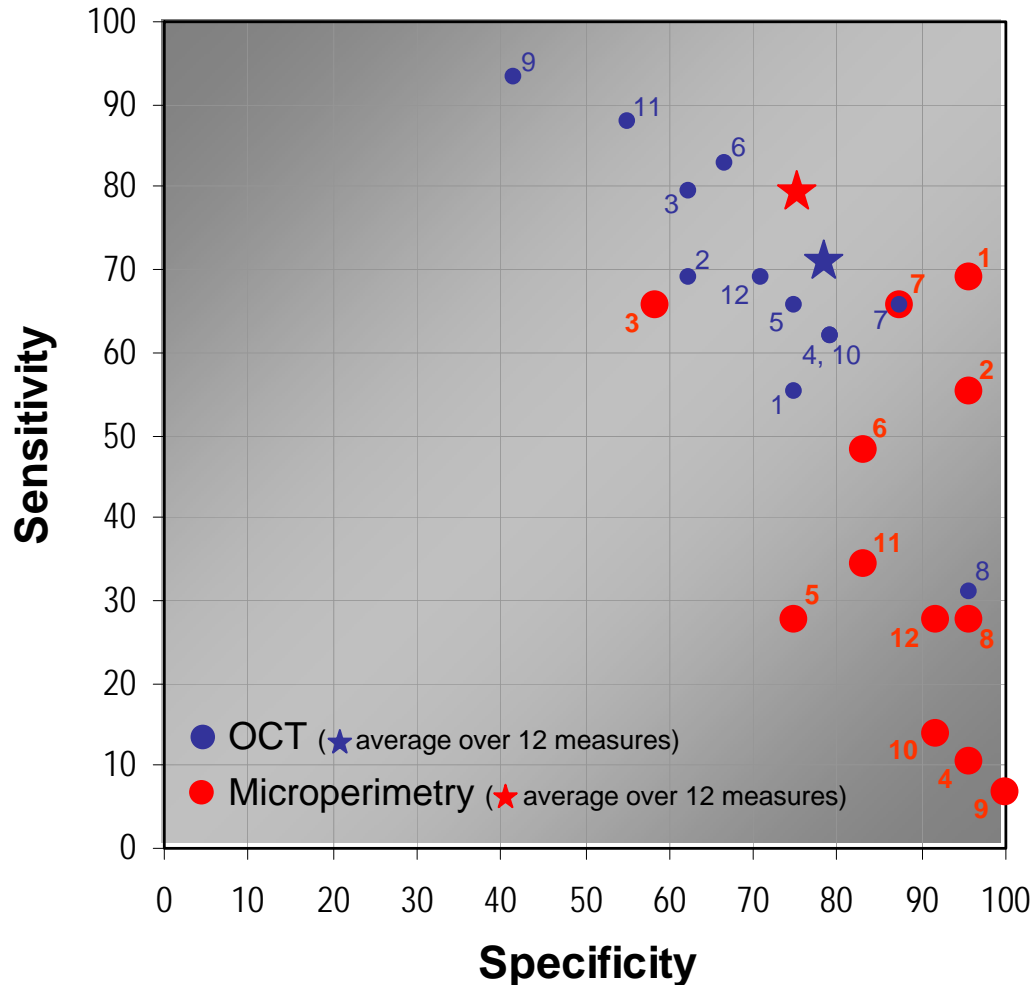
(mean values)



Comparison among thickness profiles: ANOVA with repeated measures, $F_{[22,913]}=9.74$, $p<0.0001$
 In all retinal sectors glaucoma group provide lower thickness mean values than the other two groups
 ○ Sectors in which OH group mean values are significantly ($p<0.05$) lower than normal ones

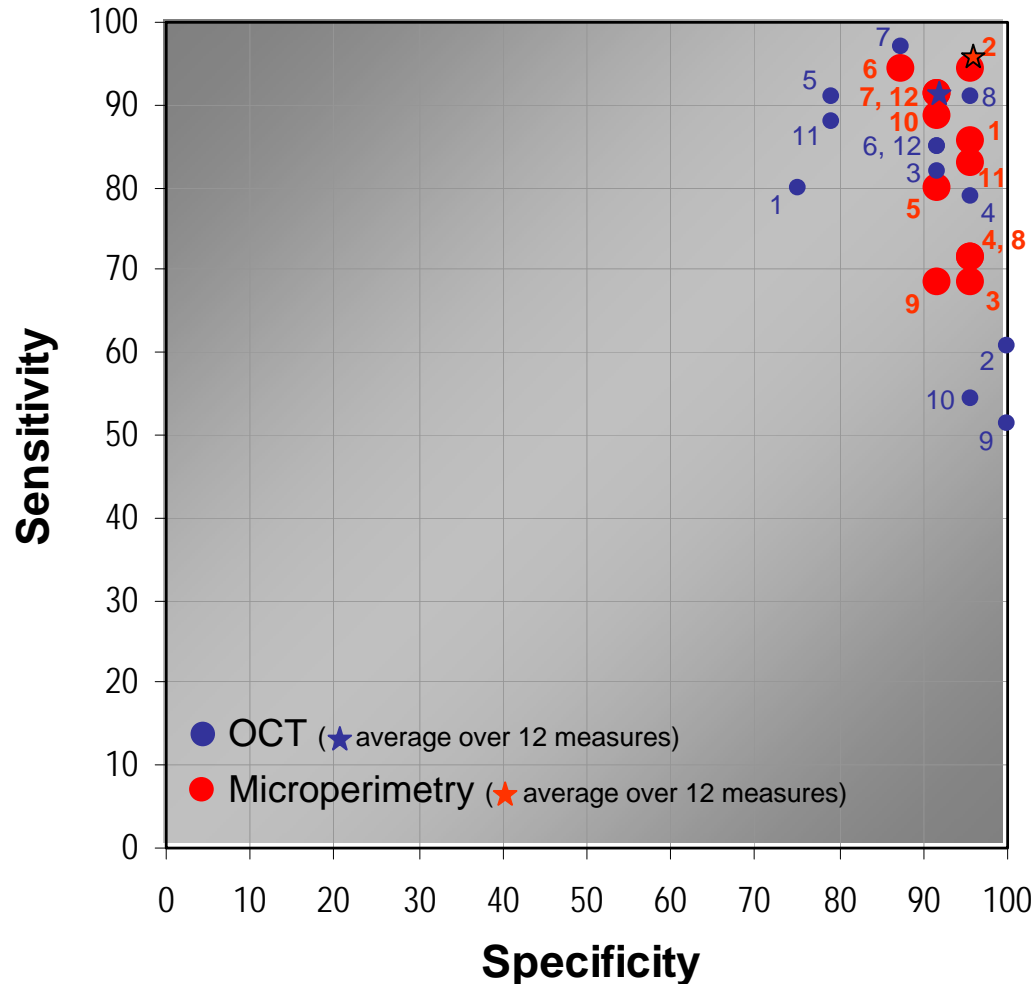
Peripapillary evaluation

Best tradeoff between sensitivity (ocular hypertension) and specificity (normality) for each of 12 retinal sectors



Peripapillary evaluation

Best combination of sensitivity (glaucoma) and specificity (normality) for each of 12 retinal sectors



DISCUSSION

OUR DATA:

- ❖ **CONFIRM** the progressive specific **reduction in thickness of peripapillary RNFL** with progressive **glaucomatous damage** (normal vs OH vs glaucoma) documented by peripapillary OCT.
- ❖ **DOCUMENT** the **loss of peripapillary sensibility** of RNFL quantified with peripapillary microperimetry **in OHT and glaucomatous vs control eyes.**

❖ **REVEAL** that in glaucomatous eyes microperimetry data are more sensitive than OCT in identify pathologic subjects.

❖ **SHOW** that peripapillary microperimetry may be used to diagnose and monitor RNFL damage, not only in glaucomatous but also (and more important) in OH eyes.

REFERENCES

- Leung CK, Chan WM, Yung WH, Ng AC, Woo J, Tsang MK, Tse RK. Comparison of macular and peripapillary measurements for the detection of glaucoma: an optical coherence tomography study. *Ophthalmology*. 2005 Mar;112(3):391-400.
- Wollstein G, Schuman JS, Price LL, Aydin A, Beaton SA, Stark PC, Fujimoto JG, Ishikawa H. Optical coherence tomography (OCT) macular and peripapillary retinal nerve fiber layer measurements and automated visual fields. *Am J Ophthalmol*. 2004 Aug;138(2):218-25.
- Midena E, Radin P.P, Pilotto E, Ghirlando A, Convento E, Varano M. Fixation pattern and macular sensitivity in eyes with subfoveal choroidal neovascularization secondary to age-related macular degeneration. A microperimetry study. *Semin Ophthalmol*. 2004, Mar-Jun;19(1-2): 55-61.
- Wollstein G, Schuman JS, Price LL, Aydin A, Stark PC, Hertzmark E, Lai E, Ishikawa H, Mattox C, Fujimoto JG, Paunescu LA. Optical coherence tomography longitudinal evaluation of retinal nerve fiber layer thickness in glaucoma. *Arch Ophthalmol*. 2004 Apr;123(4):464-70.
- Medeiros FA, Zangwill LM, Bowd C, Vessani RM, Susanna R Jr, Weinreb RN. Evaluation of retinal nerve fiber layer, optic nerve head, and macular thickness measurements for glaucoma detection using optical coherence tomography. *Am J Ophthalmol*. 2005 Jan;139(1):44-55.
- Leung CK, Chan WM, Hui YL, Yung WH, Woo J, Tsang MK, Tse KK. Analysis of retinal nerve fiber layer and optic nerve head in glaucoma with different reference plane offsets, using optical coherence tomography. *Invest Ophthalmol Vis Sci*. 2005 Mar;46(3):891-9.
- Miglior S. Microperimetry and glaucoma. *Acta Ophthalmol Scand Suppl*. 2002;236:19.
- Orzalesi N, Miglior S, Lonati C, Rosetti L. Microperimetry of localized retinal nerve fiber layer defects. *Vision Res*. 1998 Mar;38(5):763-71.
- Okada K, Watanabe W, Koike I, Tsumamoto Y, Mishima H.K. Alternative method of evaluating visual field deterioration in very advanced glaucomatous eye by microperimetry. *Jpn J Ophthalmol* 2003;47, 178-181.
- Zeimer R, Asrani S, Zou S, Quigley H, Jampel H. Quantitative detection of glaucomatous damage at the posterior pole by retinal thickness mapping. A pilot study. *Ophthalmology*. 1998 Feb;105(2):224-31.