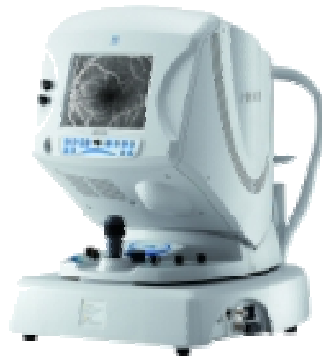

---

## F-10 - The NIDEK Digital Ophthalmoscope

---



### Digital Ophthalmoscope F-10

**The NIDEK F-10** is a scanning laser angiograph, able to provide unsurpassed level of detail in fundus imaging. F-10 has 4 different laser sources for various kind of observation (invasive and non-invasive):

Infrared, Red, Green, Blue.

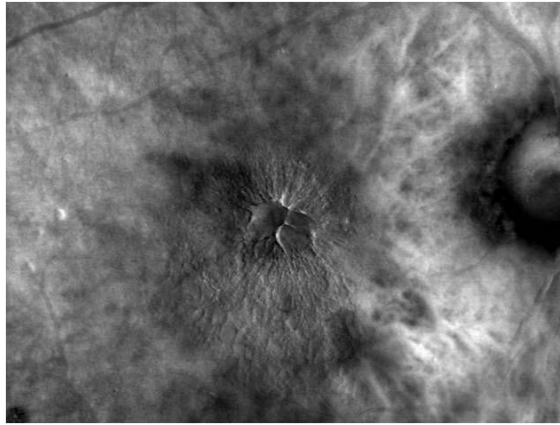
With NIDEK F-10 you can perform:

- Fluorescein and Indocyanine angiography (also simultaneously)
- IR reflectometry
- Red Free Imaging by green laser
- Autofluorescence
- Blue reflectometry (for the most internal retinal layers)
- Red reflectometry for the deepest layers and choroid observation.

---

## F-10 - The NIDEK Digital Ophthalmoscope

---



Cystoid Macular Edema

With Retro-Mode - Non invasive technique

It's also possible to observe the retinal fundus by means of the innovative Retro Mode imaging technique, that provides an exclusive retro-illumination capable to better detect retinal pathologies and alterations in a non-invasive way.

NIDEK F-10 can process the fundus images in real time with the new DCO technique (Differential Contrast Ophthalmoscopy) increasing the detail of the observed structures.

NIDEK F-10 is an incredibly versatile device for retinal imaging, for the most common macular pathologies analysis, for diabetic retinopathy (thanks to the wide angle field of view) and for glaucoma.

---

## F-10 & Age-Related Macular Degeneration

---

ARVO 2009 Program# / Poster#: 4915 / A448

### **Multimodal Integrated Approach to Atrophic Age-Related Macular Degeneration**

*E. Pilotto, S. Vujosevic (\*), E. Convento, R. Melis, P. Sportiello, S. Segalina, E. Midenà*

Department of Ophthalmology, University of Padova, Padova, Italy;  
(\* ) Fondazione G.B. Bietti per l'Oftalmologia, IRCCS, Roma, Italy

Purpose: To investigate functional and retinal morphologic changes in patients with atrophic age-related macular degeneration (AMD).

Methods: Fourteen consecutive patients (20 eyes), with non exudative AMD with an area of geographic atrophy of at least 1.3 mm<sup>2</sup> (0.5 MPS disc area) were studied by means of Spectral domain OCT, fundus color photo, fundus autofluorescence (FA), digital ophthalmoscope using blue, green, red and IR laser and a retromode system. All patients underwent static (fixation and sensitivity) and kinetic microperimetry, preferential hyperacuity perimetry (PHP). All examinations were performed during the same day and examined in a masked fashion.

Results: Fundus autofluorescence showed at least one hypo-autofluorescent (hypo-AF) area in all cases. In all cases PHP was positive. Kinetic Microperimetry detected a dense scotoma exactly corresponding to the hypo-AF areas in 13 eyes (65%) whereas in seven cases (35%) the hypofluorescent area was not characterized by a uniformly dense scotoma. Fixation was predominantly central in 11 eyes (55%), poorly central or eccentric in 9 eyes (45%). In eight cases (40%) fixation was next to or surrounded by a hypo-AF area. In 16 eyes (80%) atrophic areas were present in the peripheral retina.

Conclusions: Residual retinal function may be present in hypo-AF areas and these may be the site of fixation. PHP is positive in atrophic AMD but cannot distinguish among different morphologic changes causing metamorphopsia. In atrophic AMD morphologic changes may be detectable in the peripheral retina.

---

## F-10 & Drusen

---

ARVO 2009 Program# / Poster#: 5262 / A123

### **Retinal Drusen Detection Using the Nidek F-10 SLO in Retro-Mode**

*J.M. Gibson, J. Acton, E. Berrow, P. Galsworthy, H. King, L. Quant,  
K. Whitehouse*

Vision Sciences, Aston University, Birmingham, Birmingham, United Kingdom

Purpose: We conducted a small study to assess the novel, retro - mode imaging technique of the NIDEK F-10 scanning laser ophthalmoscope, for detecting and quantifying retinal drusen.

Methods: Fundus photographs of 4 eyes of 2 patients taken in retro-mode on the Nidek F-10 SLO were graded independently by 6,experienced, masked fundus graders for the presence of retinal drusen , and compared to stereo colour fundus photographs taken with a Topcon TRC-50DX camera.

Results: The mean number of retinal drusen detected in retro mode was 142.96+/- 60.8, range 63-265, and on colour fundus photography mean of 66.6+/-32.6, range 26-177. All observers independently detected approximately twice as many drusen on retro-mode than colour fundus photography ( $p<0.0001$ , Student's paired t-test) . The statistical significance of interobserver variation in drusen detection was  $p=0.07$  on colour fundus photography , and  $p=0.02$  on retro mode (ANOVA).

Conclusions: The retro-mode of the F-10 camera uses infrared laser and an aperture with a modified central stop, with the aperture deviated laterally from the confocal light path. This forms a pseudo -3D image which is a new means of detecting abnormalities in the deeper retinal layers. Retro-mode imaging of retinal drusen using the F-10 Nidek SLO is a highly sensitive technique for detecting and quantifying retinal drusen , and detected twice as many drusen than colour fundus photography. This small pilot study suggests that this novel type of imaging may have a role in the future detection and analysis of retinal drusen, a field that is likely to become increasingly important in future AMD prevention studies.

## F-10 & Drusen

---

ARVO 2008 Program# / Poster#: 3218 / D998

### **Non-invasive Evaluation of Age-Related Maculopathy by Indirect Viewing Using a New Scanning Laser Ophthalmoscope**

*S. Ishiko, A. Yoshida, H. Kagokawa, Y. Kato, A. Takamiya, E. Sato, K. Fukui, F.J. Van de Velde (\*), S. Oshima, J. Akita*  
Depart. of Ophthalmology, Asahikawa Medical College, Asahikawa, Japan  
(\* Ophthalmology, Schepens Retina Associates Foundation, Harvard Medical School, MA

Purpose: To determine the usefulness of noninvasive evaluation of age-related maculopathy (ARM) by indirect viewing using a new scanning laser ophthalmoscope (SLO).

Methods: Fundus examination, fluorescein angiography, and optical coherence tomography were performed in 24 eyes of 12 patients (mean age  $\pm$  SD, 70.4  $\pm$  10.8 yrs) with ARM. SLO findings were observed noninvasively with a diode laser (790 nm), by direct viewing with a confocal aperture that has a central small aperture, and by the two kinds of indirect viewing (the dark-field mode with a ring aperture that has a central stop and the retro mode with a new confocal aperture that is off-center from the optical axis).

Results: Drusen were clearly detected and in greater numbers on topographic imaging using the SLO by in direct viewing especially in retro-mode compared with photography. An area of high reflectivity observed using the dark-field mode corresponded to choroidal neovascularization (CNV) detected by angiography, but the area was larger than that observed on angiography. Retinal cystic changes on the CNV were observed clearly using retro-mode. In some cases, these findings, which are barely visible using a fundus camera, were observed even in patients with a cataract.

Conclusions: SLO indirect viewing, especially in retro-mode, precisely demonstrated drusen noninvasively and not only the vascular abnormalities but also the surrounding structural changes in ARM. This new device is valuable for evaluating structural changes and helpful for studying the relationship with functional changes in ARM.

---

## F-10 & Diabetic Macular Edema

---

ARVO 2009 Program# / Poster#: 3297 / A315

### **Diabetic Macular Edema Phenotypes: The Imaging Perspective**

*E. Midena, M. Casciano, E. Bottega, E. Benetti, S. Vujosevic*  
Department of Ophthalmology, University of Padova, Padova, Italy;  
Fondazione GB Bietti, IRCCS, Roma, Italy

**Purpose:** Diabetic macular edema (DME) shows variable clinical characteristics with unpredictable results to local treatment, probably reflecting different phenotypes. The aim of this study was to evaluate the role of structural and functional macular imaging in the characterization of DME patterns.

**Methods:** One hundred twenty one eyes of 75 diabetic patients with untreated DME underwent: best corrected visual acuity determination (BCVA, logMAR), slit lamp biomicroscopy, fluorescein angiography, OCT (mean central field (CF) retinal thickness, DME pattern, and spectral domain volume), fundus autofluorescence (FAF): absent or increased FAF (IFAF: single and multiple spots; IFAF area quantification), retro-mode scanning laser ophthalmoscopy and microperimetry. Sensitivity values are expressed as the median of mean retinal sensitivity of each study group.

**Results:** Thirty five eyes had normal FAF, 86 IFAF (28 single spot IFAF, 58 multiple spots IFAF). Retinal sensitivity over areas with IFAF was 10.5 dB (vs 15.2 dB in normal areas,  $p < 0.005$ ). Retinal sensitivity of the CF vs FAF was: 14.6 dB normal FAF, 12.10 dB single spot and 10.9 dB multiple spots IFAF ( $p < 0.05$ ). A significant correlation was found between area of IFAF, positive retro-mode imaging and CF retinal sensitivity ( $r = -0.4, p = 0.01$ ). Cystoid OCT-pattern and macular volume were correlated to both presence and dimension of IFAF and retro-mode imaging ( $p < 0.05$ ), whereas sponge-like and subfoveal neuroretinal detachment were not correlated. OCT-CF thickness did not correlate to FAF pattern and retro-mode imaging ( $p = 0.1$ ). BCVA did not correlate either to FAF pattern or area of IFAF.

**Conclusions:** The use of an integrated structural and functional retinal imaging approach allows to identify some (new) different DME phenotypes, which may be related to treatment prognosis when prospectively evaluated.

---

## F-10 & Cystoid Macular Edema

---

Int Ophthalmol DOI 10.1007/s10792-008-9274-7

### **Cystoid macular edema in polypoidal choroidal vasculopathy viewed by a scanning laser ophthalmoscope**

*Motoshi Yamamoto, Akitaka Tsujikawa, Shiho Mizukami, Norimi Miyoshi, Nagahisa Yoshimura*

Department of Ophthalmology and Visual Sciences, Kyoto University Graduate School of Medicine, Kyoto, Japan

Purpose: Visual prognosis for polypoidal choroidal vasculopathy (PCV) is reported to be relatively good. However, some eyes in the end-stage of PCV show cystoid macular edema (CME) with severe loss of vision.

Methods: We examined two eyes with CME in the endstage of PCV.

Results: The fundus of each of these eyes was examined noninvasively with a new commercially available scanning laser ophthalmoscope (SLO) in the retro-mode with an infrared laser. In the retromode, scattered light that passed the aperture deviated laterally, giving a shadow to the silhouetted cystoid spaces, enabled visualisation of the CME. In each eye, although no cystoid spaces were detected on fundus photographs, monochromatic images obtained with an SLO in the retro-mode showed numerous cystoid spaces on the disciform scar.

Conclusions: SLO in the retro-mode can show each cystoid space located in any layer of the retina, and allows us to detect the extent of the CME.

---

## F-10 & Diabetic Rethinopaty

---

ARVO 2009 Program# / Poster#: 5272 / A133

### **Findings in Diabetic Retinopathy With New Indirect Viewing Using Scanning Laser Ophthalmoscope**

*K. Suzuma, E. Tsuiki, N. Miyamura, T. Kumagami, A. Fujikawa, T. Kitaoka*  
Department of Ophthalmology & Vis Sci, Nagasaki Univ Grad Sch of BioMed Sci, Nagasaki, Japan

Purpose: Recently, fundus examination is becoming more important because detailed information can be obtained by using modern fundus examination equipments. F-10 (Nidek, Gamagori, Japan) is a scanning laser ophthalmoscope and has four different light sources and 8 different apertures. We determined the usefulness of noninvasive evaluation of diabetic retinal pathologies with the new indirect viewing system using scanning laser ophthalmoscope (SLO).

Methods: We examined diabetic macular edema (DME) and proliferative diabetic retinopathy (PDR) using SLO indirect viewing, a long wavelength laser (790 nm), and a new confocal aperture that is off-center from the optical axis (retro-mode). A spectral-domain optical coherent tomography (SD-OCT) was used to confirm the retinal pathology observed with retro-mode.

Results: The retinal vasculature was observed clearly with 532 nm green light. With the retro-mode, distribution of the cystoid spaces was so clearly shown on topographic imaging in DME. OCT was especially useful to know depth distribution of cystoids spaces, however, horizontal distribution was more easily understandable by the retro mode. Fibrovascular proliferation and vitreous changes were also seen clearly with retro-mode.

Conclusions: The SLO retro-mode is helpful for evaluating the precise retinal changes in diabetic retinopathy. Although OCT gives detailed information on retinal pathologies, the information by OCT is most useful to know vertical distribution in the retina. Simultaneous use of SLO such as F-10, allows more detailed observation of retinal diseases.



---

## F-10 & Diabetic Rethinopaty

---

ARVO 2008 Program# / Poster#: 4257 / A350

### **A Novel Imaging Modality for the Relaxed Confocal Slo Reveals Pseudo-Stereopsis in Macular Disease Entities**

*S. Oshima, J. Akita, K. Mizuno, S. Ishiko, A. Yoshida, F.J. Van de Velde (\*)*  
Depart. of Ophthalmology, Asahikawa Medical College, Asahikawa, Japan  
(\*) Ophthalmology, Schepens Retina Associates Foundation,  
Harvard Medical School, MA

Purpose: To demonstrate and interpret a novel imaging modality for the new developed relaxed confocal scanning laser ophthalmoscope (SLO).

Methods: A new cSLO is equipped with confocal apertures that are placed off-center from the optical axis. Characteristics of our new aperture are the oblique asymmetric "Tyndall" and indirect retro-illumination. Such an imaging modality shows more retinal detail but with a typical lateral shadowing of topographical irregularities. This causes the impression of depth or shape by the observer (Ramachandran, 1988). A wavelength of 790 nm has been used for retinal imaging in the examples that encompass 11 cases with macular disease such as macular hole, cystic edema, and drusen.

Results: Minute retinal radiating striae have been observed consistently around the macular holes. In branch vein retinal occlusion with macular edema, the extent of the cystic changes in the retina with adjacent retinal folds are visualized in a pseudo-stereopsis manner. Subtle topographical irregularities in the RPE-Bruch's membrane layer, caused for example by the presence of drusen stand out clearly.

Conclusions: The often pronounced pseudo-stereopsis shape effect helps in the 3-D evaluation of macular disease entities. These qualitative images are helpful for interpreting the structural changes in macular disease with corresponding quantitative 3D or 2D optical coherence tomography data.